

# Fabricating radiographic stents in implant treatment planning

James F. Fondriest, DDS and David C. McClenahan, DDS

**Abstract:** This article provides a step-by-step procedure for producing radiographic stents. Two common treatment scenarios are explored.

Computed tomography (CT) studies can be used to determine the suitability, appropriate sites and the size of the implant to be placed. They also provide information on the need for pre-implantation ridge surgery.

These studies can be enhanced with the use of radiographic markers that can show the location and tooth contours of the proposed restoration,<sup>1-2</sup> as well as the use of interactive software (SIM-Plant, Columbia Scientific). SIM-Plant allows the implant team to analyze CT data on their personal computers. This software allows the manipulation of the three-dimensional data to provide maximum information on the anatomic structures, bone quality and quantity, and it can be used to measure accurately in any dimension.<sup>3</sup>

By using radiographic markers at the time of scanning, the surgeon and restorative dentist can plan the exact placement of implants with respect to embrasures, cemento-enamel junction of adjacent teeth and emergence profiles relative to the planned contour of the anticipated prosthetic restoration.<sup>4</sup>

Radiographic preplanning also allows the restorative dentist to anticipate the prosthetic parts necessary to complete the treatment plan. A more

predictable time and cost estimate can therefore be made for the patient. This cumulative knowledge helps to further implant restoration predictability.

This article features a method of fabricating radiographic treatment planning stents for use in cross-sectional radiography (linear tomographs or CT scans). Each method is broken down into steps for convenient reference.

## Case 1: Posterior edentulous mandible

1. Duplicate and mount study casts (Fig 1).

2. Wax up preliminary treatment plan and duplicate in stone or develop a composite (Triad, Dentsply) model<sup>5</sup> (Fig 2).

3. Make a suckdown template of 1 mm clear shim (Biocryl, Great Lakes Orthodontics) using a clear acrylic sheet (Biostark, Great Lakes Orthodontics) over the hard model (Fig. 3).

4. Trim excess plastic to allow for ease of placement and removal from the duplicate hard model (Fig. 4).

5. Mix barium sulfate USP (white powder that can be procured from radiology clinic at hospital or from local pharmacist) with acrylic powder (Jet, Lang Dental Manufacturing) in a ratio of one part barium sulfate, 10 parts powder (Fig. 5).

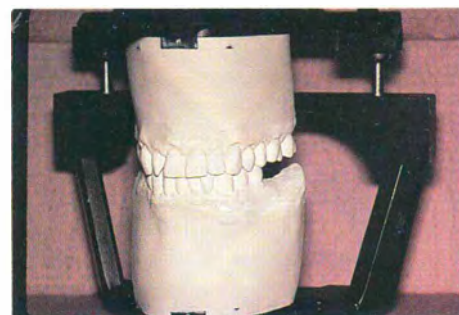

Figure 1. Mount study casts.

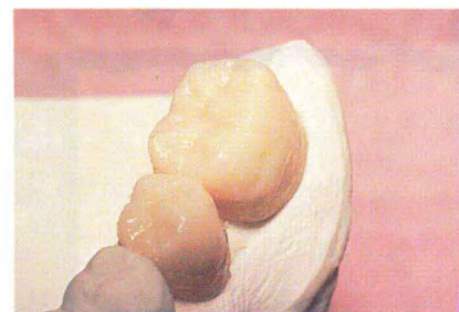


Figure 2. Diagnostic wax-up of planned restoration using Triad composite.

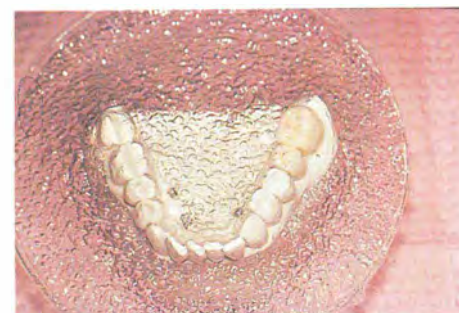


Figure 3. Suckdown template of diagnostic model.

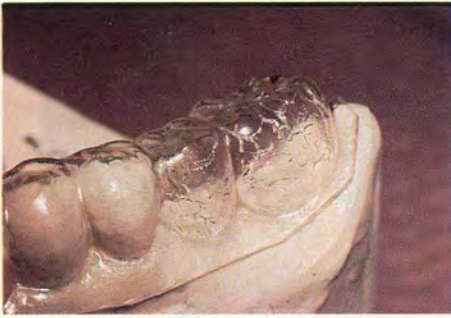

Figure 4. Trimmed template on duplicate study cast.



Figure 5. Radio-opaque barium sulfate is mixed in measured amounts into Jet acrylic powder.




Figure 6. Branemark 1.5-mm surgical pilot drill used to bore screw hole markers into barium entrained teeth.

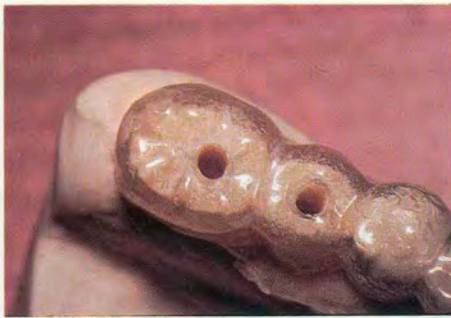

Figure 7. Occlusal view of holes bored into template parallel to axis of occlusal load.

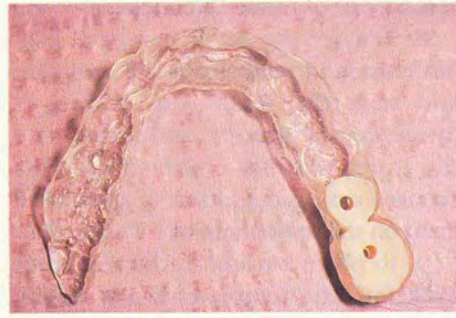


Figure 8. Gingival aspect shows the barium entrained teeth within the template.

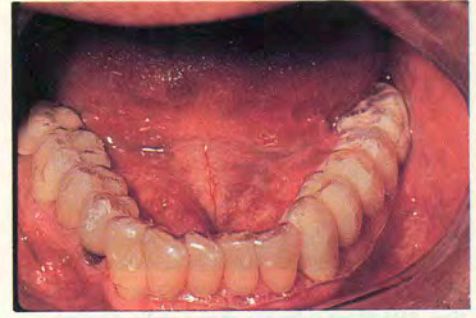

Figure 9. The completed radiographic stent should be easily placed by the patient into the mouth.



Figure 10. Lab produced clear acrylic replica of denture.



Figure 11. Sil-Tech lab putty captures detailed contours of external surface of denture replica.

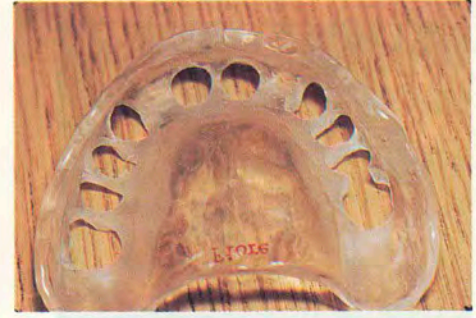

Figure 12. Remove the true contour of each tooth selected as a potential implant receptor site.

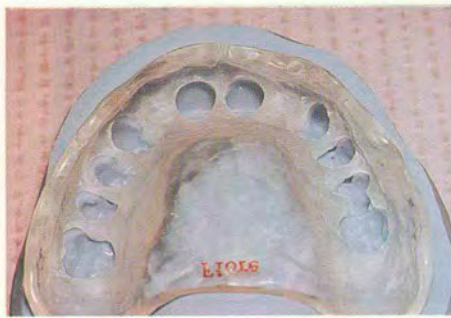

Figure 13. The denture replica is replaced in the Sil-Tech impression. The denture tooth contours in the lab putty can be seen through the holes in the modified denture replica.

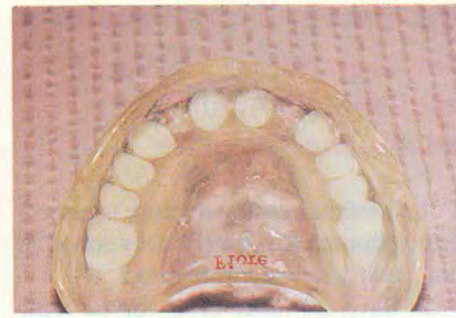

Figure 14. Barium entrained acrylic has replaced the drilled out denture teeth of the denture replica.

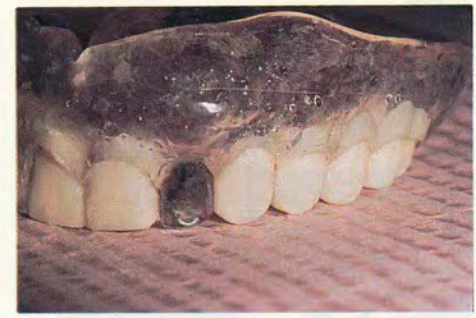

Figure 15. Embrasures and cusp heights of the radio-opaque teeth have been accentuated.

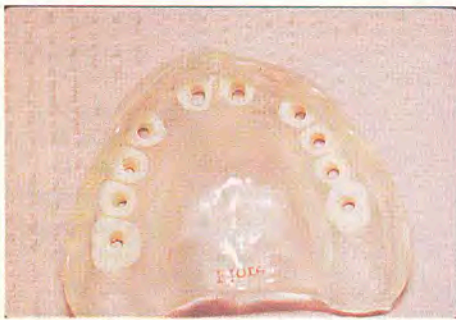


Figure 16. Screw hole markers have been bored into teeth.

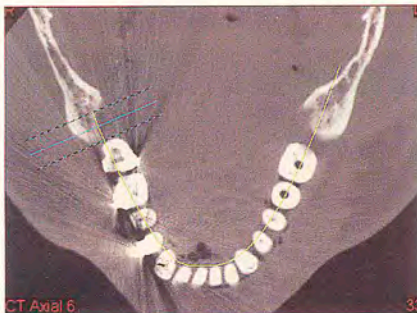


Figure 17. Horizontal cut through entire dentition. SIM-Plant software shows radio-opaque markers in Case 1. The 10:1 Jet/barium sulfate mix doesn't produce scatter radiographically.

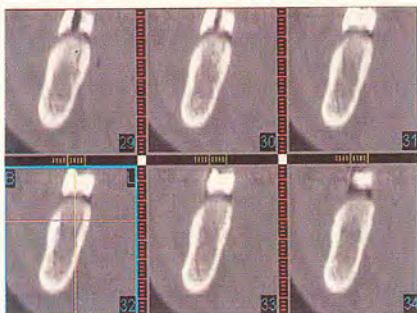


Figure 18. Cross sections through the Case 1 stent placed at 1-mm increments. Cuts 29 and 30 show bucco-lingual location of gingival end of fixture.

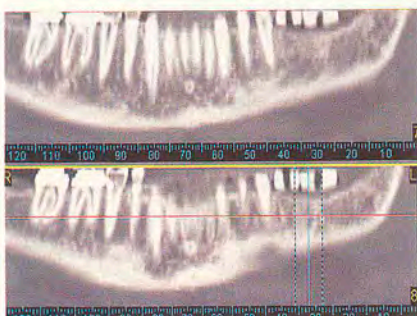


Figure 19. Panoramic view from SIM-Plant analysis shows mesiodistal locations marked by screw holes in stent.

6. Mix in monomer and pour the barium entrained liquid acrylic into template in the area of the wax-up.

7. Lubricate edentulous ridge of duplicate model (without wax-up) and place template over second model when acrylic is in dough stage. The barium entrained Jet mix will take the shape of the edentulous ridge on the gingival aspect and have a cusp fossae shape on the occlusal aspect. A good co-adaptation of the acrylic to the tissue will allow for a good radiographic assessment of tissue thickness.

8. Remove the newly hardened barium entrained teeth from the template and trim the flash. Cut a deeper fossae/central groove, and accentuate the interproximal embrasures. This ensures easy recognition of individual teeth on the tomograph or CT software.

9. Replace barium entrained teeth back into the template. If not stable, then secure teeth into template using superglue.

10. Drill a hole through the template and the barium entrained tooth starting from the central fossae or slightly buccal to fossae (wherever you plan to center your occlusal load from the opposing arch). Direct drill into the center of the ridge (hopefully this will be close to the axis of load). Use a 1.5-mm diameter Branemark surgical pilot drill (no. SDIB004 Nobelpharma, Goteborg, Sweden) (Figs. 6-8).

11. Instruct the patient to return to the office to confirm that he or she can personally place the stent into their mouth so it can be repeated at the CT facility (Fig. 9).

### Case 2: Full-arch reconstruction with implant fixtures in edentulous maxilla

1. Confirm existing denture is esthetically, phonetically, functionally sound. If not, make a new denture setup.

2. Have lab make clear acrylic replica of denture (Fig. 10).

3. Take impression of exterior contours of denture with Sil-Tech lab putty (Williams\Ivoclar North America,




Figure 20. A fixture is dropped into cross-sectional image and manipulated to point towards the screw hole, aiding fixture sizing.

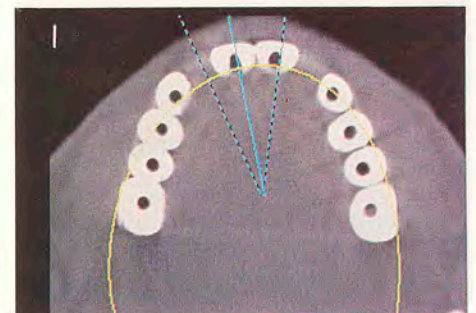


Figure 21. Horizontal cut through stent of Case 2.

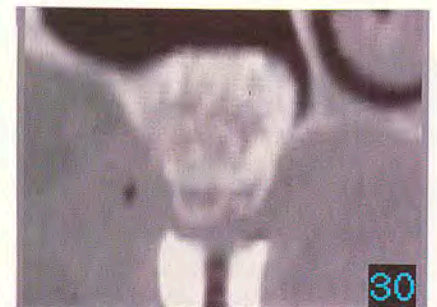

Figure 22. SIM-Plant cross section of Case 2 stent in first molar region. Tissue is thin and sinus augmentation (indicated by stronger signal) appears adequate for fixture placement.

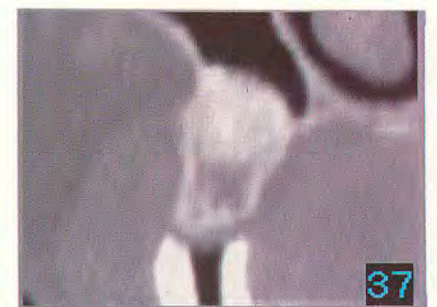

Figure 23. Case 2 cross section in premolar area shows a likely angulation of the fixed abutment to be at least 15 degrees from the fixture axis. This information allows a restorative team member to plan prosthetic parts before surgery.

Amherst, NY) (Fig. 11).

4. Use an H79SG carbide acrylic bur (Brasseler, Savannah, GA) to remove full contours of each denture tooth that could potentially be an implant receptor site (Fig. 12).

5. Replace modified denture replica into lab putty impression (Fig. 13).

6. Mix barium sulfate with Jet powder in 1:10 ratio and mix with monomer. Pour into holes of teeth just removed from denture replica.

7. Remove denture replica when barium entrained acrylic is hard and trim flash, cut deeper central groove of posterior teeth, and accentuate interproximal embrasures (Figs. 14-15).

8. Use Branemark surgical pilot drill to bore screw hole markers into barium entrained teeth (Fig. 16).

9. Have patient return for try-in. Confirm incisal edge position, phonet-

ics and occlusion.

## Summary

Some of the results from using radio-opaque markers are remarkable (Figs. 17-23).

This article describes a fabrication technique that will greatly enhance the amount of information gleaned from cross-sectional radiographs.

*Dr. Fondriest has a private practice with a focus on implant prosthetics and reconstructive dentistry and maintains a private practice in Lake Forest. Dr. McClenaban is a diplomate of periodontics and practices in Lake Forest and Libertyville.*

## References

1. Mccall RA, Rosenfeld AL. Influence of residual ridge resorption patterns on

implant fixture placement and tooth position. Part II: Presurgical determination of prosthesis type and design. *Int J Periodont Rest Dent* 1992;12:33-51.

2. Pesun IJ, Gardener FM. Fabrication of a guide for radiographic evaluation and surgical placement of implants. *J Prosthet Dent* 1995;95:548-52.

3. Sonick M, Abrahams J, Faiella RA. A comparison of the accuracy of periapical, panoramic, and computerized tomographic radiographs in locating the mandibular canal. *Int J Oral Maxillofac Implants* 1994;9:455-60.

4. *Dental Implantology Update*. Morton L. Parel ML, ed. Interactive radiographic diagnosis and case planning for implants. 1994;5(7):49-55.

5. Tarantola GJ, Becker IM. Definitive diagnostic waxing with lightcured composite resin. *J Prosthet Dent* 1993;70:315-9. ♦

Dr Fondriest - Primary Author

Contact: <https://lakeforestdentalarts.com>

# EXERCISE SOUND JUDGEMENT STEP UP TO DENTECH

The DENTECH Dental Practice Management System will improve the overall health of your dental practice. You'll breathe easier knowing that you're reaching your financial target "heart" rate with the many features of this comprehensive software package, including:

- Automatic Appointment Scheduling
- Insurance Estimation
- Clinical Integration
- Clinical Notes
- Electronic Claims
- Windows 95® or UNIX®

Lose the financial "fat" associated with late payments and lost appointments and build financial "muscle" with improved accounts receivable and more efficient scheduling. Gain flexibility with easy data integration between DENTECH and clinical workstations.



**Let DENTECH help your practice**

Get in shape — **Call**

**1-800-233-4998 today to discuss your "personal" DENTECH fitness program!**



31275 Northwestern Hwy, Suite 140 • Farmington Hills, MI 48334 • Phone: 800-233-4998 • Fax 810-855-1688  
Copyright © 1996. All names and trademarks are the property of their respective company.

**"Visit us at Booth 2302 during CDS Midwinter Meeting"**