

ESTHETIC REPAIR OF THE DENTAL CONSEQUENCES OF CELIAC DISEASE: A CASE REPORT



by James F. Fondriest, DDS
Lake Forest, IL
jimfondriest@cs.com

Matthew R. Roberts, CDT,
AACD Accredited Member
(AAACD)
Idaho Falls, ID
www.teamaesthetic.com

ABSTRACT

Hypocalcification of her tooth enamel had created occlusal and esthetic problems for a 26-year-old patient with celiac disease. Celiac disease is an autoimmune digestive disorder that damages the villi of the small intestine and interferes with absorption of nutrients from food. This disease can cause the improper development of enamel on adult teeth. The combination of bruxism with weak and poorly developed enamel had caused significant loss of tooth structure for this patient. Bonded composite did not serve well on functional occlusal surfaces. Full fixed prosthodontic coverage of her teeth was performed. The details of creating a customized appearance of the prosthesis for this patient are discussed.

A fairly common oral manifestation of celiac disease is abnormal tooth shape and/or appearance.

INTRODUCTION

Celiac disease is a digestive disorder that damages the small intestine and interferes with absorption of nutrients such as calcium from food.¹ People who have celiac disease cannot tolerate a protein called gluten, found in wheat, rye, and barley. Gluten is found mainly in foods but may also be found in products we use every day, such as stamp and envelope adhesive, certain medicines, and vitamins. When people with celiac disease eat foods containing gluten, their immune system responds by damaging the finger-like villi of the small intestine. When the villi become damaged, the body

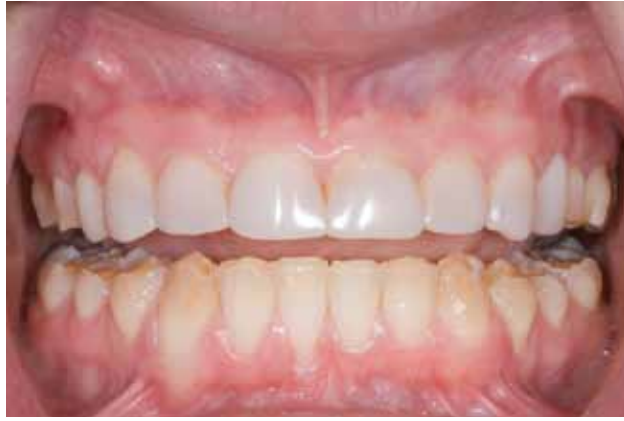

Figure 1

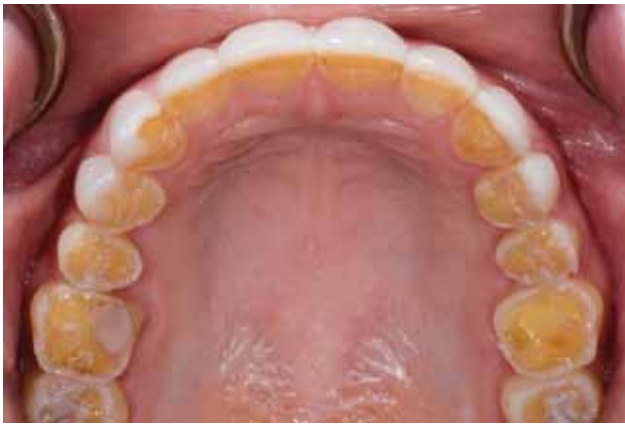

Figure 2

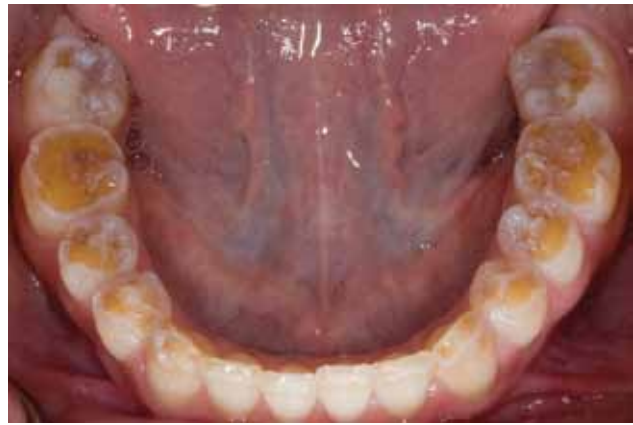

Figure 3

Figures 1-3: Celiac disease was the cause of this enamel/dentin dysplasia. The teeth did not retain bonded composite well and displayed low occlusal wear resistance. Unlike the composite that was applied to the occlusal surfaces, which chipped off quickly, the anterior composite will stay for years.

is unable to absorb nutrients into the bloodstream, which can lead to malnourishment. Failure to thrive during childhood development is a common indicator of celiac. Common signs of celiac disease include anemia, delayed growth, weight loss, and joint problems; and the bones become weak, brittle, and prone to fracture. Celiac disease is a genetic condition that can be triggered by events such as surgery, pregnancy, childbirth, viral infection, or severe emotional stress. The

only treatment for celiac disease is a lifelong gluten-free diet.

A fairly common oral manifestation of celiac disease is abnormal tooth shape and/or appearance. The teeth can be slightly small, widely spaced, and discolored with hypocalcified enamel (Figs 1-3). Patients with dental enamel defects of the entire secondary dentition should be screened for celiac disease even in the absence of gastrointestinal symptoms.² There can also be recur-

rent aphthous stomatitis. This disease affects one in 100 individuals, and 97% of those affected are undiagnosed.³

PATIENT HISTORY AND GOALS

The patient discussed here had been diagnosed with celiac disease at age 13. Although she continued to have occasional minor gastrointestinal flare-ups, her medical/dietary therapy had mainly quieted the manifestations of the disease after

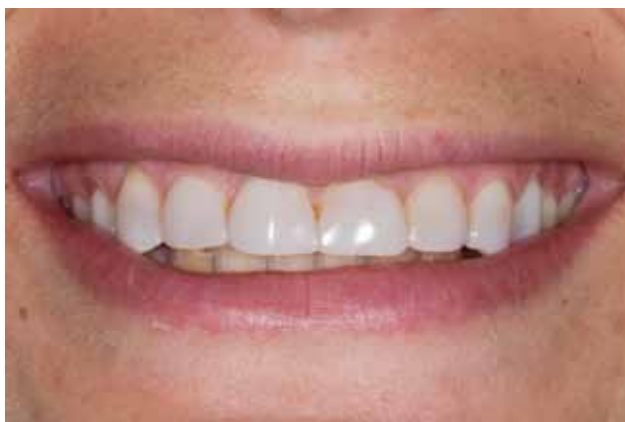

Figure 4: The recently placed composite bonding significantly improved the smile display, but the composite margins became stained soon after placement.

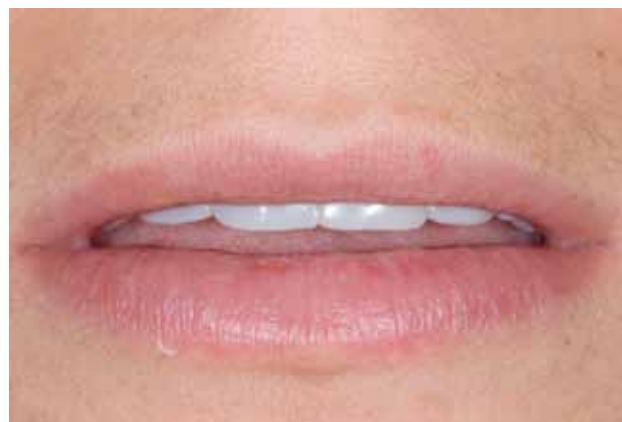

Figure 5: Commissure-to-commissure image of tooth display while the lips are at rest, or in the "M" position.⁵

diagnosis. The damage to her teeth had been done as the teeth were being formed prior to diagnosis.

She was unhappy with the esthetics of her smile. She presented at age 26 with composite bonding that had been applied to the buccal surfaces of her maxillary front teeth, which had been maintained for 18 months (Fig 4). Although the marginal integrity was already staining and failing, the patient's former dentist reported that the composite improved the esthetics of her smile greatly. Previous composite restorations had not been retained for very long, especially on chewing surfaces or functional occlusal surfaces. The qualities of her enamel and dentin as a result of celiac disease might have affected the bond strength of the composite, compromising the longevity of her previous restorations. She had been referred to us to have her teeth restored by more permanent and esthetic means. The goals were to create an improved esthetic display, establish ideal tooth anatomy, and more permanently impede the ongoing changes that had been occurring in her bite.

TREATMENT PLAN

Due to the poor bonding qualities of the teeth, nighttime bruxism, and the ongoing loss of vertical dimension, it was decided to do full-coverage restorations on all of her teeth. Due to the lack of certainty in reliably achieving a strong dentin bond, the tooth preparations were designed with maximum retention and resistance form. All posterior teeth would be restored with porcelain-fused-to-gold crowns and pressed Empress (Ivoclar Vivadent; Amherst, NY) crowns in the anterior teeth.

The planning phase included acquiring diagnostic photographs of the patient, radiographs, and mounted models; and ascertaining the patient's desires and expectations. The more information-sharing that was done, the more the patient took an active role in the planning process. She had definite opinions on what specific shapes she wanted her new teeth to have, as well as the level of brightness and translucency. Her request was to have "natural-looking teeth, but a little brighter." The patient did not have the knowledge or vocabulary to describe her

understanding of what a beautiful smile was, but she (and her mother) indicated that they would know it when it was achieved. Much time was spent clarifying what their definition of natural was.

TREATMENT

DISCUSSION

For a 26-year-old female, the normal tooth display of the maxillary centrals when the lips are at rest is 5 mm to 6 mm.⁴ In this patient, however, only 1.5 mm to 2 mm of #8 and #9 were visible hanging down below the upper lip (Fig 5). She had a normal lip mobility of approximately 8 mm, and the gingival display was normal and was deemed symmetrical enough in full smile. The centrals measured only 8 mm in vertical length, rendering a square look. A normal length-to-width ratio for the centrals would be achieved by adding 2.5 mm to 3 mm in length. The vertical dimension of occlusion was opened 3 mm as measured from the incisal edges of the maxillary and mandibular centrals. The majority of the addition was to the maxillary arch, adding posterior occlusal thickness in varying amounts

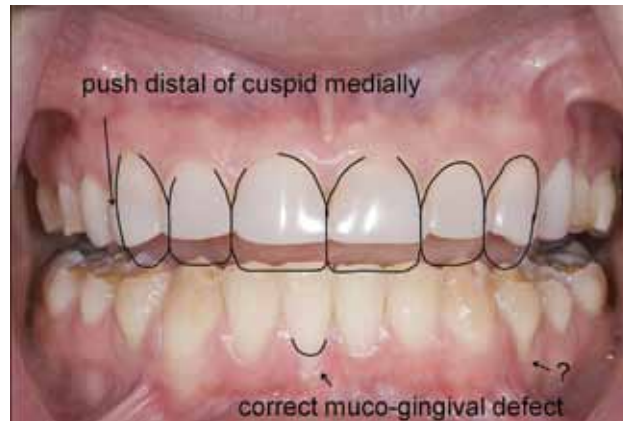

Figure 6: Line drawings of agreed-upon outline form of future teeth used as a guide in creation of the wax-up. A periodontal consultation recommended a muco-gingival connective tissue graft on the buccals of #21 and #25.



Figure 7: Laboratory putty matrix impression of the wax-up used as a buccal surface reduction guide.

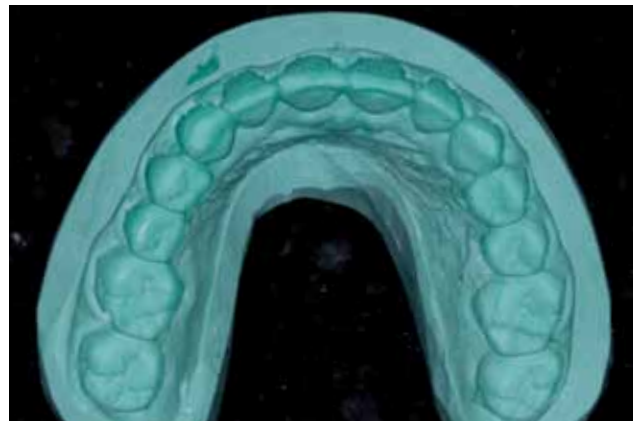


Figure 8: Laboratory putty matrix impression of the wax-up used for provisional fabrication.

to level the occlusal plane. Opening the vertical dimension served three purposes: It restored some vertical dimension that was being lost by the enamel breakdown faster than the patient was adapting, it allowed for a flat occlusal plane that otherwise would have been uneven after the front teeth were lengthened, and it allowed the lengthening of the maxillary incisors without steepening the guidance.

IMPORTANCE OF THE PROVISIONALS

Although we are sometimes referred new patients who think, imagine, and assume everything is possible, the majority of clients do not know what really is possible and even if they do, they do not know what the dentistry will look like in their own mouth. Many practitioners have the ability to create digital images that represent potential outcomes.^{6,7} These are helpful but can easily give patients unrealistic expectations due to the fact that changing real teeth is far more difficult than doing it digitally. Applying com-

posite mock-ups to the teeth will give the patient a good impression of how it could look, and often the contours of this mock-up are used in fashioning the provisionals and ultimately the final restorations. When changing the incisal edge position significantly, mock-ups alone may not be an adequate substitute for diagnostic longer-term provisionals.^{8,9} It helps to both see and “feel it” to judge it. Wearing provisionals for a month or two would also serve to better develop my patient’s understanding of what was possible esthetically and offer her more op-

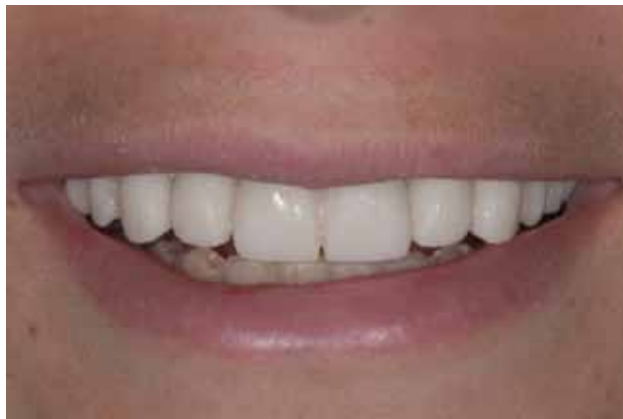

Figure 9: The patient wore indirect acrylic provisionals on the upper arch for several months.



Figure 10: Right lateral view of maxillary provisionals.



Figure 11: Left lateral view of maxillary provisionals.

portunity for growth, appreciation, and involvement in the process.

VISUAL GUIDANCE FOR THE LABORATORY

When the patient's vision was fully understood, a variety of portraits, intraoral images, scanned magazine photographs, and line drawings (Fig 6) were then collated in a PowerPoint™ presentation. This served as the laboratory prescription for a wax-up of the treatment plan. The visual guidance that the laboratory technician received as to how to create the esthetic contours of the wax-up in this presentation was of

far greater value than any written document. The wax-up was a rendering of my understanding of what the patient wanted esthetically, and would also serve as the first representation of her final smile. All too often the final restoration serves as the only rendering, especially with implant restorations. This limits the many lessons that the intermediate steps of doing a wax-up and provisionals can provide.

IMPORTANCE OF THE WAX-UP

From a treatment perspective, the wax-up was more than just as a

guide for the laboratory to complete the project. The wax-up gave a better feel for just how much reduction needed to be done to move her teeth into preferred orientations and positions.¹⁰ The wax-up allowed detailing for ideal placement of the cusps-fossae relationships and the ridge blade placements for the posterior teeth. The wax-up can allow tooth reduction guides to be made (Fig 7) that represent the desired location of the external surfaces of the final anterior restorations, thus directing tooth preparation to achieve adequate and appropriate restoration

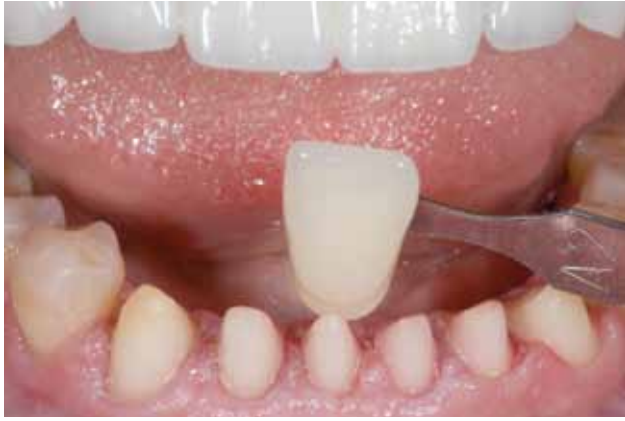

Figure 12: Stump shade prior to completing the lower front six teeth, one week after insertion of crowns ##6-11. Treatment throughout the mouth was done one sextant at a time.

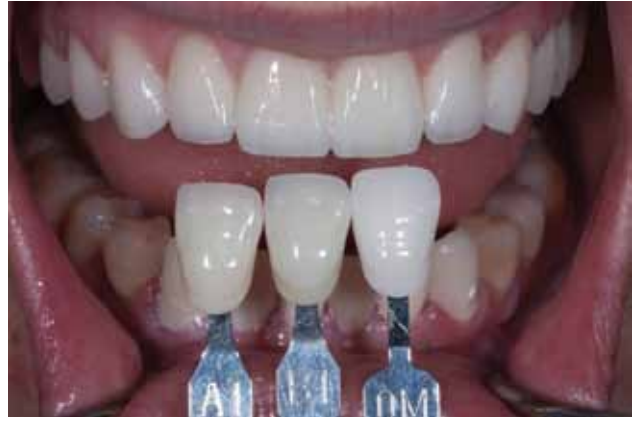

Figure 13: Shade prior to completing the lower front six teeth, One week after insertion of crowns ##6-11.

thickness.¹¹ The reduction guides for this case proved very valuable, as their use reduced significantly the amount of tooth reduction from the normal crown preparation. Another version of a lab putty matrix of the wax-up (Fig 8) was used to fabricate acrylic provisionals indirectly in the laboratory.

PROVISIONALIZATION

When the wax-up was completed and the reduction guides and putty matrix impressions were created, the patient was scheduled for preparation and provisionalization of the maxillary arch. The lower arch was temporarily built up with composite to help open the vertical. It was at the first placement of the maxillary provisionals that the patient saw her new smile start to materialize. No matter how well the contours were planned with the preoperative photographs and wax-up, until we placed these provisionals into her mouth we did not know what it would look like or how it interacted with the tissue to create scallop forms and inter-dental papillae.^{9,12} She got to see for herself what the amended length, shapes, incisal embrasures, etc. that she chose for her

teeth looked like behind the drape of her own lips (Figs 9-11).

Wearing the provisionals allowed the patient to adapt to the changes in the phonetic interplay between the teeth and the occlusal changes that had been created by the significant prosthetic reorientation of her teeth prior to the delivery of her final restorations.^{13,14} Due to the increased functional stresses and potential for porcelain fracture from the occlusal trauma that comes with bruxism, a shallow-to-flat anterior guidance with a smooth crossover in excursive movements was created.

Often patients are startled by the quick and profound changes that can be effected through dentistry. The provisionals allow the patient to become accustomed to the changes. Occasionally a patient will pull back on the degree of change desired because of the difficulty in getting used to a new look. When they look at a smile for their entire life and suddenly it is gone, it can be disorienting. If the practitioner gives the patient the time to actually *live* in the provisionals prior to taking final impressions, the patient can be brought farther along.

LABORATORY WORK

When the maxillary provisionals had fulfilled all of the goals for esthetics, function, phonetics, and cleansability, it was time to send the case to the laboratory. Because all of the criteria for acceptance had been worked out in the provisional stage, the laboratory just had to duplicate the contours of the provisionals to achieve an esthetic and comfortable result.¹⁰ Documenting the provisionals included straight-on portraits, portraits taken from the side, close up extraoral and intraoral photographs, retracted images from all angles when teeth were together and then when they were apart, stick bite, mounted models of the provisionals, and bite registration records of the provisionals and prepared teeth. Offering a critique of the provisionals (mine and the patient's) was helpful to my technician partner. The technician was given direction as to how much artistic license there was with the duplication of the contours of the accepted provisionals.

FINAL RESTORATIONS

To decrease the level of difficulty of replacing the maxillary provision-

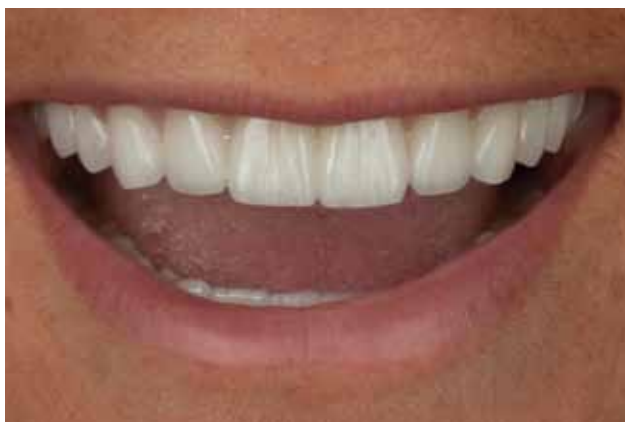

Figure 14: Postoperative full smile.

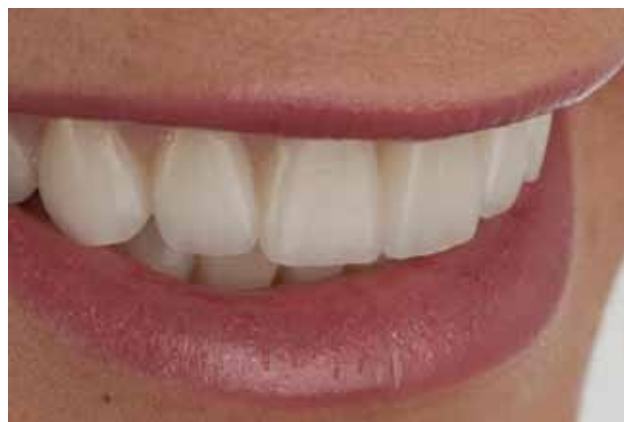

Figure 15: Postoperative lateral view of full smile.

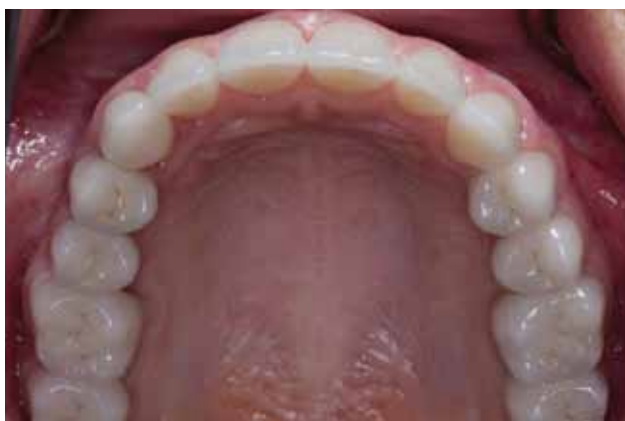

Figure 16: Postoperative maxillary occlusal view.

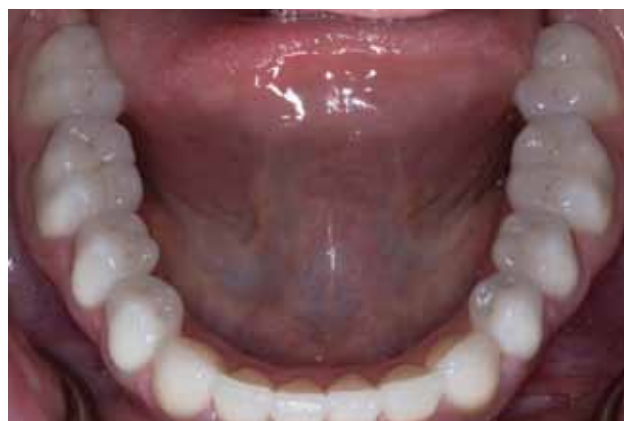

Figure 17: Postoperative mandibular occlusal view.

als with the final prosthetics, this patient was restored one sextant at a time. This way, the trauma at any given appointment was far less. No master impression required capturing more than six teeth at a time (Figs 12 & 13). This also decreased the risk of bite registration errors, which are far more frequent when doing an entire arch.

The lower arch was completed in three segments like the upper arch but without a wax-up and prolonged use of provisionals (Figs 14-18). All posterior crowns were luted with Rely X luting cement (3M ESPE; St. Paul, MN). The anterior teeth were

bonded with Optibond FL (Kerr; Orange, CA) and Rely X ARC dual-cure resin. Assuming that high bond strengths were unlikely with any cementation system, the choice of luting agents was based on what is commonly used in the office.

CONCLUSION

This patient suffered the dental consequences of celiac disease in combination with severe bruxism. The resulting significant dental attrition caused the loss of vertical dimension and diminished esthetics. A custom smile was produced by collaborating with the patient in

the design on every level of the final prostheses. Specific shapes, textures, translucency gradients, and chroma and value gradients were created to fashion this patient's definition of a beautiful smile.

Acknowledgments

The author thanks the laboratory contributions of Mark Kajfez, CDT (Waukegan, IL), who did the posterior crowns; Dave Rice, DDS (Elgin, IL), for the graphics help; and Dave McClenahan, DDS (Lake Forest, IL), for the muco-gingival grafts.



Figures 18: Images taken after the entire mouth was completed.

AACD Acknowledgment

The American Academy of Cosmetic Dentistry recognizes Matthew R. Roberts, CDT, as an AACD Accredited Member (AAACD).

References

- Green P, Cellier C. Celiac disease: medical review. *N Engl J Med*. 2007;357:1731-43.
- Pastore L, Carroccio A, Compilato D, Panzarella V, Serpico R, Lo Muzio L. Oral manifestations of celiac disease. *J Clin Gastroenterol*. 2008 Mar;42(3):224-32.
- Celiacdisease.net [Internet]. Chicago: The University of Chicago Celiac Disease Center Web site. Available from <http://www.celiacdisease.net/>.
- Vig R, Brundo G. Kinetics of anterior tooth display. *J Prosth Dent*. 1996;39(5):502-4.
- Fondriest JF. Documentation versus artistic photography. *Quint Dent Tech*. 2008;31:127-31.
- Brooks LE. Smile-imaging: the key to more predictable dental esthetics. *J Esthet Dent*. 1990 Jan-Feb;2(1):6-9.
- Flucke J. Digital dentistry: using high-tech imaging. *Dent Products Report*. 2002 Jan-Feb:55-58.
- Donovan TE, Cho GC. Diagnostic provisional restorations in restorative dentistry: the blueprint for success. *J Can Dent Assoc*. 1999 May;65(5):272-5.
- Fondriest JF. Using provisional restorations to improve results in complex aesthetic restorative cases. *Pract Proced Aesthet Dent*. 2006;18(4):217-24.
- Magne P, Magne M, Belser U. The diagnostic template: a key element to the comprehensive esthetic treatment concept. *Int J Perio Rest Dent*. 1996 Dec;16(6):560-9.
- Brunton PA, Aminian A, Wilson NH. Tooth preparation techniques for porcelain laminate veneers. *Br Dent J*. 2000 Sept 9;189(5):260-2.
- Ferencz JL. Maintaining and enhancing gingival architecture in fixed prosthodontics. *J Prosthet Dent*. 1991 May;65(5):650-7.
- Pound E. Controlling anomalies of vertical dimension and speech. *J Prosthet Dent*. 1976 Aug;36(2):124-35.
- Pound E. Let /S/ be your guide. *J Prosthet Dent*. 1977 Nov;38(5):482-9.

